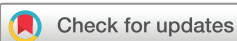

# tRNA methyltransferase 10 homologue A (*TRMT10A*) mutation in a Chinese patient with diabetes, insulin resistance, intellectual deficiency and microcephaly

Hu Lin <sup>1</sup>, Xuelian Zhou,<sup>1</sup> Xuefeng Chen,<sup>1</sup> Ke Huang,<sup>1</sup> Wei Wu,<sup>1</sup> Junfen Fu,<sup>1</sup> Yangxi Li,<sup>2</sup> Constantin Polychronakos <sup>2</sup>, Guan-Ping Dong <sup>1</sup>

**To cite:** Lin H, Zhou X, Chen X, et al. tRNA methyltransferase 10 homologue A (*TRMT10A*) mutation in a Chinese patient with diabetes, insulin resistance, intellectual deficiency and microcephaly. *BMJ Open Diab Res Care* 2020;**8**:e001601. doi:10.1136/bmjdr-2020-001601

Received 9 June 2020  
Revised 25 July 2020  
Accepted 27 July 2020



© Author(s) (or their employer(s)) 2020. Re-use permitted under CC BY-NC. No commercial re-use. See rights and permissions. Published by BMJ.

<sup>1</sup>Department of Endocrinology, The Children's Hospital Zhejiang University School of Medicine, National Clinical Research Center for Child Health, National Children's Regional Medical Center, Hangzhou, Zhejiang Province, China

<sup>2</sup>The Endocrine Genetics Laboratory, Department of Pediatrics, Research Institute of McGill University Health Centre, Montreal, Quebec, Canada

**Correspondence to**  
Dr Guan-Ping Dong;  
dgpplx@zju.edu.cn

## ABSTRACT

**Introduction** Loss-of-function mutations in tRNA methyltransferase 10 homologue A (*TRMT10A*), a tRNA methyltransferase, have recently been described as a monogenic cause of early-onset diabetes with microcephaly, epilepsy and intellectual disability.

**Research design and methods** We report a Chinese young patient who was diagnosed with diabetes mellitus as a result of a *TRMT10A* mutation.

**Results** A homozygous mutation c.496–1G>A in *TRMT10A* was identified using targeted next-generation sequencing and confirmed by PCR/Sanger sequencing. In addition to being diagnosed with diabetes, the patient also has microcephaly and intellectual deficiency. The diabetes was due to marked insulin resistance and responded very well to metformin treatment.

**Conclusion** Our case is the first report in the Asian population. It adds to current knowledge of *TRMT10A* related with young-onset non-insulin-dependent diabetes and confirms the a single previous report of insulin resistance in this syndrome. Genomic testing should be considered in children with non-insulin-dependent diabetes with intellectual disability and microcephaly. A clear genetic diagnosis is helpful for early detection and treatment addressing insulin resistance.

## INTRODUCTION

Recently, recessive mutation of tRNA methyltransferase 10 homologue A (*TRMT10A*) was reported in some families as the cause of a novel syndrome of abnormal glucose homeostasis with microcephaly, epilepsy and intellectual disability. In the present paper, we report a Chinese young patient with diabetes, intellectual deficiency and microcephaly as a result of a homozygous mutation in the *TRMT10A* gene.

## Case report

The patient had been found to have hyperglycemia for a week. The random blood glucose was 13.3 mmol/L, and the patient had no polyphagia, polydipsia, polyuria, weight loss or other abnormal symptom. The patient was

## Significance of this study

### What is already known about this subject?

- ▶ Loss-of-function mutations in tRNA methyltransferase 10 homologue A (*TRMT10A*), a tRNA methyltransferase, have recently been described as a monogenic cause of early-onset diabetes with microcephaly, epilepsy and intellectual disability.

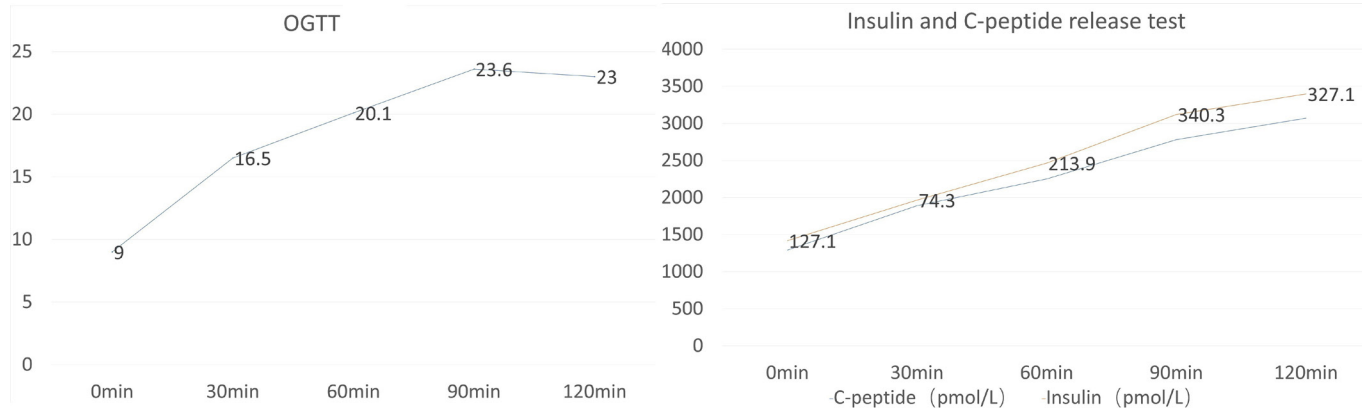
### What are the new findings?

- ▶ Our case is the first report in the Asian population. It adds to current knowledge of *TRMT10A* related with young-onset non-insulin-dependent diabetes and confirms the single previous report of insulin resistance in this syndrome.

### How might these results change the focus of research or clinical practice?

- ▶ It broadens the spectrum of *TRMT10A* mutation and its role in genetic disorders, and it also shows that genomic testing should be considered in children with non-insulin-dependent diabetes with intellectual disability and microcephaly.

the first child born to non-consanguineous parents. The pregnancy was uneventful and the child was born by a full-term cesarean section due to amniotic fluid turbidity. The child's birth weight was 2800 g, but the birth length and head circumference were not recorded. The developmental milestones were abnormal and the child gradually began to show mild intellectual disability. The child had a fever and convulsion and was diagnosed with a febrile seizure once in preschool period. The child's head circumference was 46 cm (–2.5 SD) in preschool period, while the height was 100 cm (–1.5 SD). At the time of diagnosis, the head circumference was 50 cm; the height was 143 cm (–3 SD); and the body mass index (BMI) was 15.65 kg/m<sup>2</sup>. There was no special appearance and acanthosis nigricans was absent. Glycated



**Figure 1** Results of OGTT. OGTT, oral glucose tolerance test.

hemoglobin (HbA1c) was 14.4%, and all five pancreatic autoantibodies were negative. Oral glucose tolerance test (OGTT) showed a plasma glucose of 9 mmol/L at 0 min, and 23 mmol/L at 120 min, which confirmed the diagnosis of diabetes. Insulin and C-peptide levels indicated that the pancreatic  $\beta$ -cell function was well preserved (figure 1). No other abnormality was found in laboratory tests or imaging tests, including liver and kidney functions, thyroid function, electroencephalogram (EEG) and head MRI. In addition, intelligence testing indicated intellectual deficiency, with an IQ of 47.

The patient's parents had normal heights, head circumferences and BMI, no epilepsy, no intellectual disability, no diabetes or pre-diabetes (normal OGTT results) and negative pancreatic autoantibodies, as well as the patient's sibling, with normal birth history, normal growth and development history.

### Genetic studies

Since the patient's only manifestation is isolated and mild hyperglycemia, which does not meet the criteria for either type 1 diabetes or type 2 diabetes, it was suspected that the patient had monogenic diabetes. Exome sequencing,

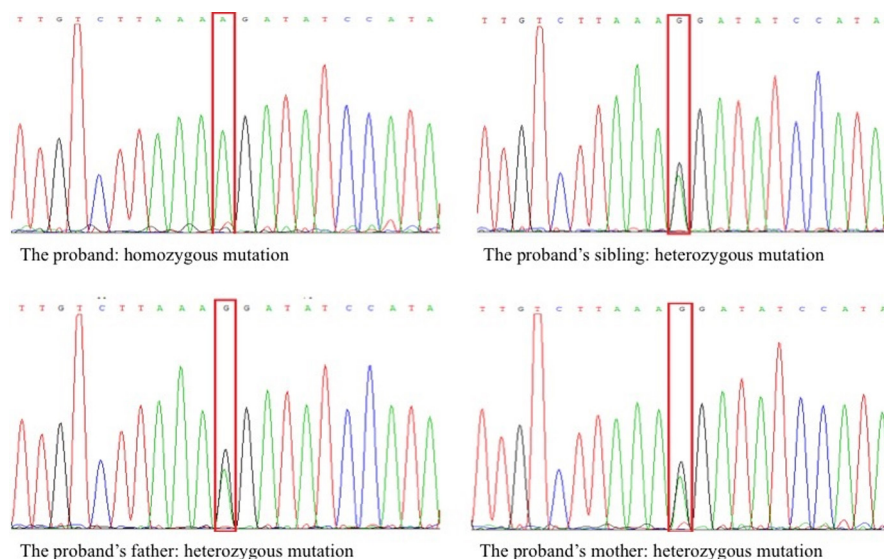
focusing on known diabetes genes, found a homozygous G to A transition in intron 5 of *TRMT10A* (NM\_152292.4: c.496-1G>A), verified by Sanger sequencing. It was homozygous in the proband and heterozygous in both the patient's parents and sibling (figure 2). Mutations of other monogenic diabetes genes were not detected.

### Continuous glucose monitoring (CGM)

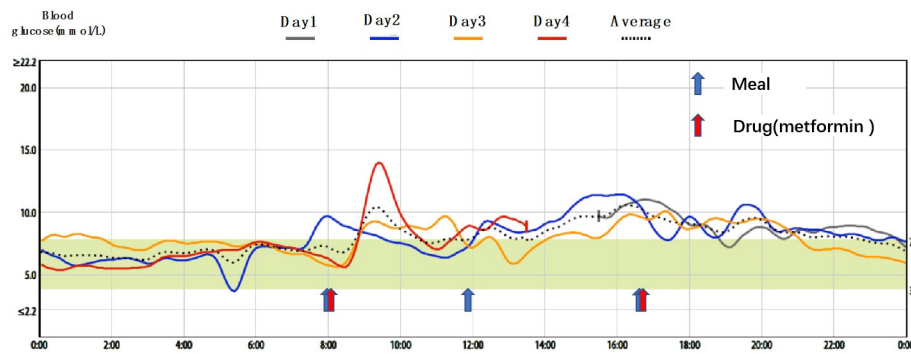
In the subsequent visit 3 months after diagnosis, the patient's HbA1c decreased to 6.8% with the treatment of metformin, and the patient received the CGM for nearly 72 hours (figure 3). Since hypoglycemia has also been reported in this syndrome, we examined the patient's daily glucose profile by CGM, which showed that the blood glucose was maintained at a stable level, with only one blood glucose value of less than 3.9 mmol/L. The average percent time on target (3.9–7.8 mmol/L) (figure 4) was 47%.

### DISCUSSION

*TRMT10A* is the orthologue most closely related to yeast *TRM10*, a protein that has tRNA m1G9 methyltransferase



**Figure 2** Genetic studies of the family.



**Figure 3** Continuous glucose monitoring of the patient for nearly 72 hours.

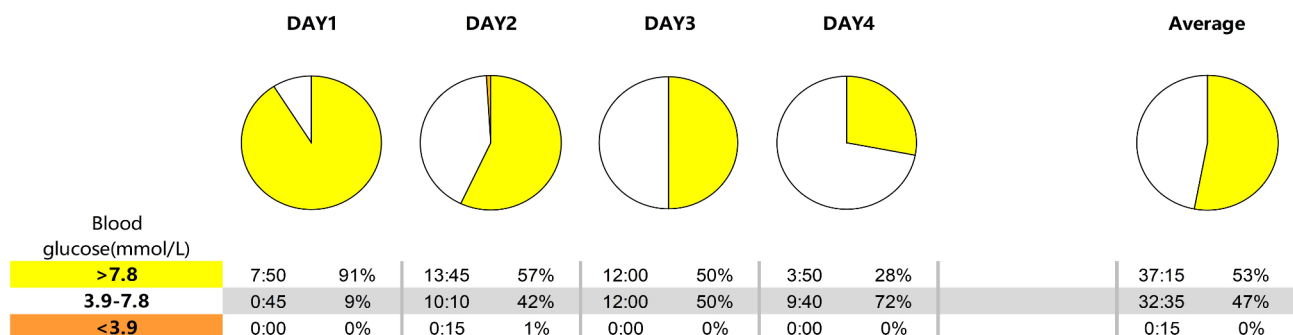
activity.<sup>1</sup> It is a nuclear protein that can be expressed in several tissues (liver, kidney, spleen, lung, and fat), but enriched in islets and the brain, the two main tissues affected in patients.<sup>2</sup> A syndrome caused by homozygous nonsense mutations in *TRMT10A* in a consanguineous patient of Moroccan origin was first described by Igoillo-Esteve *et al* in 2013, including diabetes, microcephaly, and intellectual deficiency.<sup>3</sup> A total of 11 cases were subsequently reported.<sup>4-7</sup> Our case is the 12th one and also the first report in the Asian population.

Abnormal glucose homeostasis was a common feature caused by *TRMT10A* mutations, except the two individuals reported by Narayanan *et al*, with no documented hypoglycemia or hyperglycemia. The glucose metabolism disturbances associated with mutation in *TRMT10A* include diabetes with or without ketosis, hyperinsulinemic hypoglycemia and postprandial hyperglycemia. Most individuals presented with diabetes, which was diagnosed between the ages of 9 and 28 years, while the two individuals described by Gillis *et al*<sup>7</sup> had no diabetes but hyperinsulinemia and hypoglycemia. Our patient was diagnosed with diabetes at a young age, without ketoacidosis, but accompanied by spontaneous mild hypoglycemia (recorded by CGM). According to the OGTT results, insulin resistance appeared to be the dominant pathophysiological mechanism in our patient, which confirms insulin resistance as the cause of diabetes, described in the case of Yew *et al*.<sup>5</sup> This was further confirmed by response to a subsequent treatment with metformin, with which the HbA1c decreased significantly. The mechanism by which the mutation causes insulin resistance still

remains to be elucidated. In the previous cases reported by Igoillo-Esteve *et al* and Zung *et al*,<sup>3,4</sup> the patients had well-preserved insulin secretion, suggesting that insulin resistance may be the primary event in mutations of *TRMT10A*. It has been experimentally shown that *TRMT10A* knockdown induces oxidative stress and triggers the intrinsic pathway of apoptosis in  $\beta$  cells.<sup>2</sup> This may explain the diabetes that appears as the disease progresses, but it cannot explain the hyperinsulinism and insulin resistance, which suggests a more complex  $\beta$ -cell dysfunction. Whether the insulin resistance, clearly demonstrated in our case and in Yew *et al*,<sup>5</sup> is secondary to the chronic hyperinsulinemia or primary remains to be seen. The absence of obesity would indicate a primary defect.

In all the reported cases, microcephaly was a feature in common, but the degree of severity appeared to vary. Among them, eight cases were reported to have mild to severe microcephaly in the birth history,<sup>4-7</sup> and the case reported by Zung *et al*<sup>4</sup> had persistent microcephaly. Our patient's head circumference at birth was not recorded but became obvious as our patient grew, as reported by Igoillo-Esteve *et al*.<sup>3</sup>

All the individuals had intellectual disability, including language development and motor development. In addition, epilepsy was common except the individual reported by Zung *et al*.<sup>4</sup> The two individuals reported by Narayanan *et al*<sup>6</sup> had abnormal EEG that showed as symmetric, bilateral, frontally dominant polyspike and wave discharges, consistent with generalized epilepsy, with abnormal brain MRI that showed mild Fluid attenuated inversion



**Figure 4** Percent time on target of the patient for nearly 72 hours.

recovery (FLAIR)/T2 hyperintensities in the peritrial white matter, although the EEG and brain imaging of other individuals are normal (or not reported).

As for our patient, who was diagnosed with febrile seizures in preschool period, had normal EEG and brain imaging results and had no seizures since then. Besides, it is worth mentioning that our patient had a short stature without delayed puberty as the previously reported cases, except the individual reported by Yew *et al.*<sup>5</sup> *TRMT10A* microcephaly is likely related to the loss of brain volume due to increased apoptosis, which is in contrast to primary microcephaly linked to centrosome and spindle function during mitosis.<sup>8</sup> Since studies suggest that *TRMT10A* deficiency increases the amount of beta cell apoptosis, it can also increase neuronal cell apoptosis presumably.

## CONCLUSION

In summary, *TRMT10A* protein is ubiquitously present but more abundant in human brain and pancreatic islets. This was consistent with the selective involvement of brain (microcephaly and intellectual disability) and pancreatic islets (hyperglycemia and diabetes) in our patient. Insulin resistance as the cause of diabetes in our patient and in Yew *et al.*<sup>5</sup> remains to be determined. Our report provides independent confirmation of the role of *TRMT10A* mutations in this newly described syndromic form of monogenic diabetes and also expands its phenotypic description. Those children or adults who have diabetes accompanied by intellectual disability, microcephaly and epilepsy, but in the absence of obesity and autoimmunity, should be suspected of *TRMT10A* mutations and need to undergo genetic testing. Clear genetic diagnosis is conducive to early accurate treatment and follow-up of related complications from an early age.

**Contributors** G-PD developed the study concept and supervised the study. HL participated in the writing of the manuscript and also in the study design and interpretation of results. CP and JF helped with the corrections of the manuscript. YL performed the bioinformatics and literature review. XZ, XC, KH and WW summarized clinical information of the patients.

**Funding** The authors acknowledge the financial support from the National Key Research and Development Program of China (No. 2016YFC1305301), National Natural Science Foundation of China (no. 81570759) and Research Fund of Zhejiang Major Medical and Health Science and Technology & National Ministry of Health (WKJ-ZJ-1804).

**Competing interests** None declared.

**Patient consent for publication** Not required.

**Ethics approval** The original study was approved by the medical ethics committee of the Children's Hospital of Zhejiang University School of Medicine (2019-IRB-124).

**Provenance and peer review** Not commissioned; externally peer reviewed.

**Data availability statement** Data are available upon reasonable request.

**Open access** This is an open access article distributed in accordance with the Creative Commons Attribution Non Commercial (CC BY-NC 4.0) license, which permits others to distribute, remix, adapt, build upon this work non-commercially, and license their derivative works on different terms, provided the original work is properly cited, appropriate credit is given, any changes made indicated, and the use is non-commercial. See: <http://creativecommons.org/licenses/by-nc/4.0/>.

## ORCID iDs

Hu Lin <http://orcid.org/0000-0003-2253-7223>

Constantin Polychronakos <http://orcid.org/0000-0002-7624-6635>

Guan-Ping Dong <http://orcid.org/0000-0001-6389-5719>

## REFERENCES

- 1 Jackman JE, Montange RK, Malik HS, *et al.* Identification of the yeast gene encoding the tRNA m1G methyltransferase responsible for modification at position 9. *RNA* 2003;9:574–85.
- 2 Cosentino C, Toivonen S, Diaz Villamil E, *et al.* Pancreatic beta-cell tRNA hypomethylation and fragmentation link TRMT10A deficiency with diabetes. *Nucleic Acids Res* 2018;46:10302–18.
- 3 Igoillo-Esteve M, Genin A, Lambert N, *et al.* tRNA methyltransferase homolog gene TRMT10A mutation in young onset diabetes and primary microcephaly in humans. *PLoS Genet* 2013;9:e1003888.
- 4 Zung A, Kori M, Burundukov E, *et al.* Homozygous deletion of TRMT10A as part of a contiguous gene deletion in a syndrome of failure to thrive, delayed puberty, intellectual disability and diabetes mellitus. *Am J Med Genet A* 2015;167A:3167–73.
- 5 Yew TW, McCreight L, Colclough K, *et al.* tRNA methyltransferase homologue gene TRMT10A mutation in young adult-onset diabetes with intellectual disability, microcephaly and epilepsy. *Diabet Med* 2016;33:e21–5.
- 6 Narayanan M, Ramsey K, Grebe T, *et al.* Case report: compound heterozygous nonsense mutations in TRMT10A are associated with microcephaly, delayed development, and periventricular white matter hyperintensities. *F1000Res* 2015;4:912.
- 7 Gillis D, Krishnamohan A, Yaacov B, *et al.* TRMT10A dysfunction is associated with abnormalities in glucose homeostasis, short stature and microcephaly. *J Med Genet* 2014;51:581–6.
- 8 Woods CG, Parker A. Investigating microcephaly. *Arch Dis Child* 2013;98:707–13.